



Chenin Orthodontics

Stephen T. Chenin, DDS

David A. Chenin, DDS

www.CheninOrthodontics.com



Member
American Association of
Orthodontists



4306 So. Eastern Avenue • Las Vegas, Nevada 89119-6016 • (702) 735-1010 • Fax: (702) 735-6823

Cosmetic Orthodontics & Invisalign

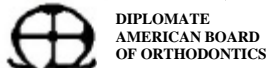
Thursday March 25, 2004

Seminar Notes

- ❖ Stephen T. Chenin, D.D.S.
 - Board Licensed Orthodontic Specialist
 - Diplomate, American Board of Orthodontics
- ❖ David A. Chenin, D.D.S.
 - Manager of Clinical Process Development, Align Technology
 - Investigator, Invisalign ClinCheck Study, Univ. of Pacific Orthodontic Dept.
- ❖ Outline
 - Dr. David Chenin
 - Understand Case Selection
 - Advantages of Invisalign
 - Overview Technology & Software
 - Update on Research & Development
 - Dr. Stephen Chenin
 - Case Presentations
 - Discuss Other Cosmetic Orthodontic Appliances
- ❖ Invisalign Manufacturing Video
- ❖ What is Invisalign?
 - Aesthetic orthodontic treatment developed for adults and teens who can benefit from straight teeth
 - A series of clear, custom made, removable Aligners created to effectively move teeth into their desired position
 - Combines proven orthodontic science with 3-D computer graphics to project tooth movement.
- ❖ Invisalign Use
 - Aligners are worn 24 hours and removed for eating, drinking, brushing and flossing
 - Patients wear each set of Aligners in two-week intervals.
- ❖ Case Selection
 - Cases typically performed without the need for auxiliary appliances
 - Mild & Moderate Crowding
 - Mild & Moderate Spacing
 - Phase II Treatment / Orthodontic Relapse
 - Mild & Moderate Narrow Arches
 - Mild & Moderate Deep Bites
 - Combination Restorative Therapy
 - Cases typically requiring the need for auxiliary appliances
 - Crossbites
 - Sagittal Discrepancies (Class II, III)
 - Severe Deep Bites
 - Severely Narrow Arches
 - Severe Spacing
 - Severe Crowding
 - Openbites

Copyright 2004 Chenin Orthodontics, All Rights Reserved

Practice Limited Exclusively to Orthodontics and Dentofacial Orthopedics for both Children and Adults
Cosmetic Orthodontic Treatment Available – Invisalign, Clear Braces, or Low Profile Gold / Silver Braces



Chenin Orthodontics

Stephen T. Chenin, DDS

David A. Chenin, DDS

www.CheninOrthodontics.com



Member
American Association of
Orthodontists

invisalign[®]

4306 So. Eastern Avenue • Las Vegas, Nevada 89119-6016 • (702) 735-1010 • Fax: (702) 735-6823

➤ Case Studies

- Mild Crowding Case
 - Proclination and correction of deep bite
 - Chenin DA, Trosien AH, Fong PF, Miller RA, Lee RS. Orthodontic treatment with a series of removable appliances. J of Am Dent Assoc 2003; 134(9):1232-9.
- Moderate Spacing Case
- Deepbite Case
- Anterior teeth Edge-to-Edge Case
- Severe Crowding Case
 - Expansion and proclination.
 - Womack WR, Ahn JH, Ammari Z, Castillo A. A new approach to correction of crowding. Am J Orthod and Dentofac Orthop 2002; 133(3):310-316.
- Class II & Class III Cases
 - Posterior IPR to improve esthetics
- Restorative Veneer Case
 - Opened bite with Invisalign the veneered anterior
 - Norris RA, Brandt DJ, Crawford CH, Fallah M. Restorative and Invisalign: A New Approach. J Esthet Restor Dent 2002; 14(4):217-224.
- Implant Case
- Bicuspid Extraction Cases
 - Auxiliaries needed for these cases
 - Research cases shown
 - Boyd RL, Vlaskalic V. Three-dimensional diagnosis and orthodontic treatment of complex malocclusions with the Invisalign[®] Appliance. Semin Orthod 2001; 7(4): 274-293.

➤ Auxiliary Techniques

- What movements are less predictable?
 - Severe rotations of cylindrical teeth
 - Extrusion
 - Large Translation
- Achieving Less Predictable Movements
 - Severe rotations of cylindrical teeth
 - ◆ (*buttons & elastics*)
 - Extrusion
 - ◆ (*buttons & elastics*)
 - Large Translation
 - ◆ (*sectionals & archwire*)
- Same as traditional braces use of various auxiliary techniques for achieving specific movements
 - Positioners - Detailing Movements
 - Bite Planes - Intrusion / Extrusion
 - Palatal Expanders - Expansion
 - Magnets - Anchorage / Movements
 - Elastics - Sagittal & Vertical Movements
 - Springs - Midlines / Space Closure

Copyright 2004 Chenin Orthodontics, All Rights Reserved

Practice Limited Exclusively to Orthodontics and Dentofacial Orthopedics for both Children and Adults
Cosmetic Orthodontic Treatment Available – Invisalign, Clear Braces, or Low Profile Gold / Silver Braces



Chenin Orthodontics

Stephen T. Chenin, DDS

David A. Chenin, DDS

www.CheninOrthodontics.com



Member
American Association of
Orthodontists



4306 So. Eastern Avenue • Las Vegas, Nevada 89119-6016 • (702) 735-1010 • Fax: (702) 735-6823

- ❖ Invisalign Patient Advantages
 - Virtually invisible
 - Comfortable
 - Removable
 - Brush and floss normally
 - Less pain than traditional orthodontics
 - Patients can visualize their end result (ClinCheck®).
- ❖ Invisalign Clinical Advantages
 - Reduced risk of decalcification
 - Decreased occlusal abrasion from parafunctional habits during treatment
 - Ideal for positioning teeth for proper placement of restorations
 - Minimal additional instrumentation required
 - Visualization of Planned Tooth Movement (ClinCheck).
- ❖ Treatment Visualization Software ClinCheck™
 - Allows viewing of final outcome prior to treatment
 - Grid tools
 - Superimposition Tools
 - Ability to have different outcomes view 3D (extraction vs. non extraction)
- ❖ Publications
 - **34 Articles**
 - Journal of American Dental Association (JADA)
 - Compendium of Continuing Education in Dentistry
 - Journal of Esthetic and Restorative Dentistry
 - Journal of Clinical Orthodontics (JCO)
 - Seminars in Orthodontics
 - Etc.
- ❖ Research / Studies
 - Extremely difficult cases (University of the Pacific)
 - Speed and Materials (University of Washington)
 - Attachments (University of Florida)
 - Combination Treatment (University of Berlin)
 - 3-D Scanning (Internal)
 - Diagnosis & ClinCheck Study (University of the Pacific)
 - Various Topics (Private Practice Research)
- ❖ Teen Research
 - Preliminary findings from the Adolescent Treatment with the Invisalign Appliance study as of March 2003 have been compiled and are now available. Interim analysis indicates that: Invisalign is effective in the treatment of teens.
 - ANDY TROSIEN, DDS, MS, CHRIS PEARSON, UPDATE: EARLY TEEN STUDY DATA SHOWS EFFICACY, COMPLIANCE, Invisalign Clinical Update, Summer 2003.
 - Teens are compliant with Invisalign to achieve desired results
 - Oral hygiene is maintained in teen patients during treatment
 - Teens average wearing aligner for over 20 hours per day!
 - 2nd Molars must be fully erupted

Copyright 2004 Chenin Orthodontics, All Rights Reserved

Practice Limited Exclusively to Orthodontics and Dentofacial Orthopedics for both Children and Adults
Cosmetic Orthodontic Treatment Available – Invisalign, Clear Braces, or Low Profile Gold / Silver Braces



Chenin Orthodontics

Stephen T. Chenin, DDS

David A. Chenin, DDS

www.CheninOrthodontics.com



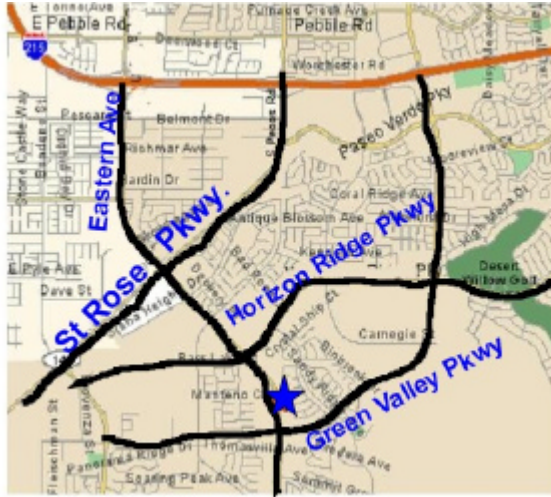Member
American Association of
Orthodontists

invisalign®

4306 So. Eastern Avenue • Las Vegas, Nevada 89119-6016 • (702) 735-1010 • Fax: (702) 735-6823

- ❖ www.invisalignncec.com
- ❖ Clinical Support
 - Customer Service: 888-82-ALIGN
 - David A. Chenin, DDS: (408) 470-1290 dchenin@aligntech.com
 - Clinical Team: (408) 470-1400 clincomm@aligntech.com

- ❖ Second office Location: ~10700 S. Eastern



- ❖ Dr. Stephen T. Chenin Case Studies
 - Invisalign Case – Mild Upper Crowding
 - Pre-tx Records, ClinCheck, Final Records
 - Proclination of incisors
 - Invisalign Case – Severe Lower Crowding
 - Pre-tx Records, ClinCheck, Final Records
 - Lower incisor extraction
 - Invisalign Case – Severe Lower Crowding
 - Pre-tx Records, ClinCheck, Final Records
 - Lower incisor extraction
 - Anterior Corssbite
 - Use of auxiliary technique for upper lateral incisor
- ❖ Other Cosmetic Orthodontic Options
 - Lingual Braces
 - Tend to be irritating on lingual oral tissues and difficult to clean
 - Invisalign, followed by Clear Braces, then Low Profile Braces are preferred
 - Low Profile Metal Braces
 - Gold Braces vs Silver Braces
 - Clear Braces (e.g. Clarity)
 - Non-Surgical Case – Severe Upper & Lower Crowding
 - Pre-tx Records, ClinCheck, Final Records

Copyright 2004 Chenin Orthodontics, All Rights Reserved

Practice Limited Exclusively to Orthodontics and Dentofacial Orthopedics for both Children and Adults
Cosmetic Orthodontic Treatment Available – Invisalign, Clear Braces, or Low Profile Gold / Silver Braces



Chenin Orthodontics

Stephen T. Chenin, DDS

David A. Chenin, DDS

www.CheninOrthodontics.com



Member
American Association of
Orthodontists

invisalign®

4306 So. Eastern Avenue • Las Vegas, Nevada 89119-6016 • (702) 735-1010 • Fax: (702) 735-6823

- Bicuspid Extractions

- ❖ Early Treatment (also know as Interceptive Treatment or Phase I Treatment)
 - Age 7: the year to remember for orthodontics
 - Key benefit from parent's & patient's perspective
 - Many other benefits of identifying orthodontic problems early
 - Benefits
 - Benefits for patient with an indication for early treatment:
 - Influence jaw growth in a positive manner
 - Lower trauma risk for protruded incisors "bucked teeth"
 - Reduce harmful oral habits & Improve speech problems
 - Improve aesthetics and self-esteem
 - Simplify / shorten treatment of later orthodontics, if it is needed
 - Reduce likelihood of impacted permanent teeth
 - Preserve or gain space for erupting permanent teeth
 - Case Study of Early Treatment
 - Age 9 Lateral incisors flared
 - Phase I: ~9 months Removable
Age 9½: Started Phase I
Age 10½: Finished Phase I
 - No treatment : ~2 ½ years
Age 10½: - 12¾: Growth Monitoring
 - Phase II: ~1½ year Braces
Age 13: Start Phase II
Age 14½: Finish Phase II

- ❖ Have Fun!!!!

Copyright 2004 Chenin Orthodontics, All Rights Reserved

Practice Limited Exclusively to Orthodontics and Dentofacial Orthopedics for both Children and Adults
Cosmetic Orthodontic Treatment Available – Invisalign, Clear Braces, or Low Profile Gold / Silver Braces